



EMG: WHICH ONE AND WHY ?

Considerations regarding Pudendal Nerve Terminal Motor Latencies (PNTML)

Eric de Bisschop - Eric Baurtant
Aix en Provence - France

Pudendal nerve goes through narrow passages which can induce entrapment neuropathies. Before broaching the subject, we must recall an entrapment is a region of localized injury and inflammation in a peripheral nerve which is caused by mechanical irritation from surrounding anatomical formations.

To evoke a pudendal nerve trunkular entrapment, two mains investigations methods can be done: Pudendal Terminal Motor Latencies and "Staged" Sacral reflexes.

Considerations regarding Pudendal Terminal Motor Latencies (PNTML)

For measuring pudendal nerve motor time conduction a special device was developed at the St Mark's London Hospital. It consists of a bipolar stimulating electrode fixed on a gloved index finger. A pair of surface recording electrodes is placed 3 cm proximally on the base of the finger. Using a rectal passway the stimulating electrode is placed near the ischial spine. The recording electrode is at the level of the anal sphincter. With this method authors describe a latency around of 2 milliseconds. We use a special finger stall on which a pair of stimulating electrodes is fixed (Mamberti-Dias - de Bisschop) that enables us to get a more precise stimulation. Needle or surface recording electrodes are into the anal sphincter or on the bulbocavernosus/bulbospongiosus muscle. Rectal or vaginal passway can be used.

PNTML has to be viewed with some scepticism:

- The test measures the terminal conduction time of the motor pudendal branches without considering the sensory ones.
- About the technical procedure we must have in mind the lack of precision of the stimulation point (difficulty to exactly locate the point, distortion of the stimulating potential by the different layers of tissues to go through).

- A latency prolongation or slowing conduction time is not specific of a compression, but only indicates a disease affecting the myelin without specifying the localisation nor the aetiology. It does not at all indicates a partial degeneration.
- Many factors can interfere with the conduction time (vascular ++, synaptic distal, vegetative reactivity, variability in the daytime...). There are differences in latencies according to different investigators. That can explain the variability and lack of stability of the recordings in an individual patient is not completely explained. There is not concensus about the normal values of the terminal conduction time.
- It cannot specify with accuracy the site of the pudendal nerve damage.
- Moreover, an entrapment above the ischial spine sometimes can reduce the terminal velocity and induce the surgeon in a false diagnostic.

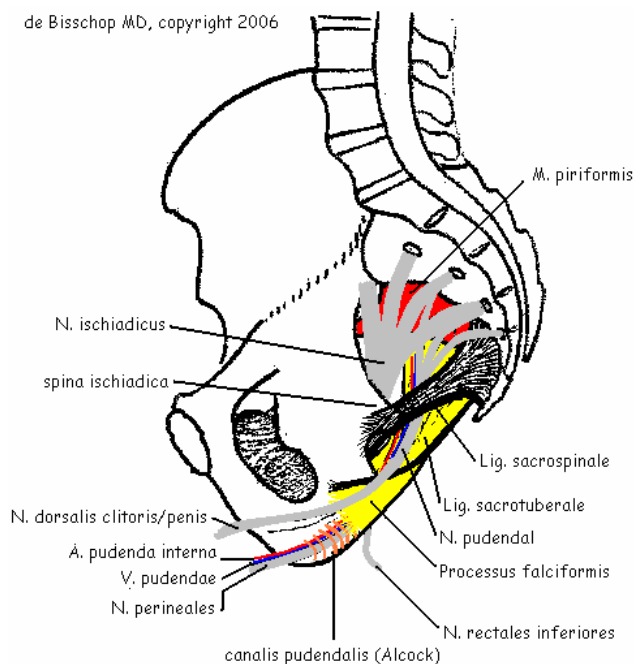
For these reasons we think this test is not very useful as a surgery indicator. It only has a dispatching role.

"Staged" Sacral reflexes

Our data analysis shows differences between the conventional anatomy and this one from electrolological investigations.

Conventional anatomy versus functional anatomy

Fig. 1: Anatomical overview : "Conventional anatomy"



The pudendal nerve takes its origins in S2, S3 and S4 roots (Fig. 1). Lateral to the sciatic nerve (*N. ischiadicus*) and the posterior cutaneous nerve of the thigh (*N. cutaneus femoris posterior*), the pudendal nerve is closely linked to the ventral face of the piriformis muscle (*M. piriformis*). The nerve descends into the infrapiriformis canal and passes under the sacrospinous ligament. Then the pudendal pathway runs through the falciform process (caudal part of the sacrotuberous ligament at its insertion on the ischiatic tuberosity) and penetrates into a tunnel (Pudendal tunnel or Alcock canal) formed by the splitting of the fascia of the internal obturator muscle (*M. obturatorius internus*). This tunnel is located with the caudal part of the levator ani muscle. Nerve branches are detached from the pudendal nerve: the dorsal nerve of the clitoris/penis (*N. dorsalis clitoridis/penis*) between the sacrospinous ligament and the falciform process; the inferior rectal nerve (*N. rectales inferiores*) in the Alcock tunnel, the perineal nerve (*N. perineales*) which is the distal part of the pudendal nerve and is completely located in the Alcock tunnel.

Bases of an "electrophysiological" anatomy

The description of the pudendal nerve is common to the medical literature. But on the other hand, our electrophysiological data show us that the nerve branches have different origins from those described in the conventional anatomy and would have a selective innervation to the muscular distribution. Moreover, the puborectal muscle (*M. puborectalis*) behaves as being innervated by the levator ani nerve (*N. levatoris ani*). The levator ani nerve crosses the ventral face of the coccygeus muscle (*M. coccygeus*) and does not pass under the sacrospinous ligament nor under the falciform process and thus avoids the Alcock tunnel.

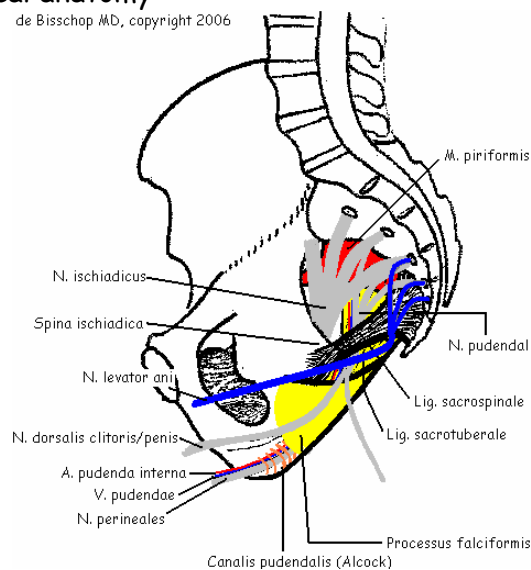
The levator ani nerve does not use the potentially compressive passway of the pudendal nerve (sacrospinous ligament, falciform process and Alcock tunnel) to come innervating the pubo-rectal muscle. The inferior rectal nerve leaves the pudendal nerve just after (some times before) passing the sacrospinal ligament. It innervates the caudal quadrant of the external anal sphincter (*M. sphincter ani externus*). It would not thus pass by the falciform process nor the Alcock tunnel. The perineal nerve passway to the ventral quadrant of the external anal sphincter crosses risk zones: sacrospinous ligament, falciform process and Alcock tunnel

Electrophysiological investigations

As a basis for an electrophysiological diagnosis we use the innervation areas of the pudendal branches and the levator ani muscle (Fig. 2)

Fig. 2. Electrophysiological anatomy

de Bisschop MD, copyright 2006



Basic concept

For us selective sacral reflexes measured from the pudendal territory is the most important way in exploring a pudendal neuralgia. Concentric needle EMG of the various perineal muscles (parts of the external sphincter of the anus) and of the puborectal muscle, terminal motor latency measurement on patients awaked and under general anaesthesia, cerebral somatosensory evoked potentials recorded on electrical stimulation of the perineal dermatomes (perineal SEP), inform us upon the pathophysiology of the entrapped nerf.

Concerning EMG and terminal latencies, it seems necessary to precise two points. We reitere what we are highlighting from a long time. A slowing of the nerve conduction is caused by demyelinative and/or metabolic lesions (compression, ischemia...) and not by a neural degeneration which leads to a loss of axons. Concerning terminal latencies, a prolonged latency is not specific of a compression but only indicates a nerve demyelinisation without specifying the localization nor the aetiology. It does not indicate a nerve a degenerative processus. It may not specify with accuracy the site of the pudendal nerve damage. Many factors can interfere with the conduction time (vascular, synaptic distal, sympathetic nervous system...). Considered alone, this test is not very useful, except in the operative procedure.

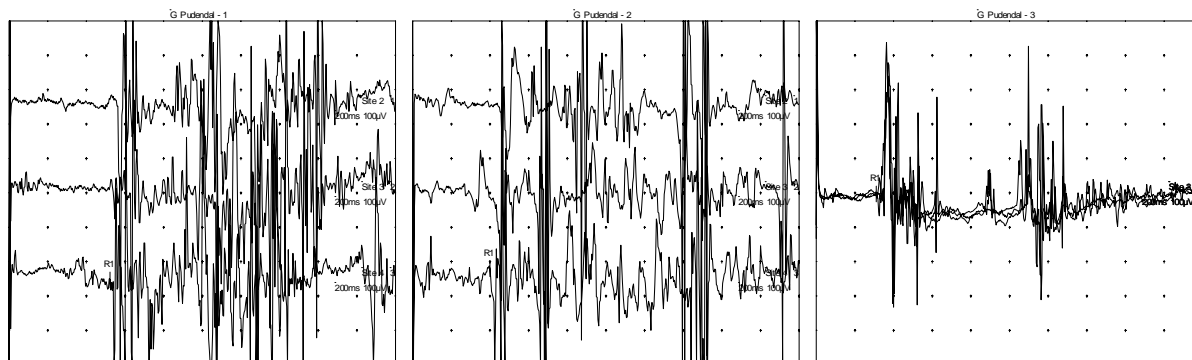
"Staged sacral reflexes" in relationship with the explored perineal muscles

Topographic investigation from anatomoelectrophysiological data

- Ventral quadrant (anterior part) of the external anal sphincter (perineal nerve). It provides informations on the global conduction of the pudendal nerve.
- Caudal quadrant (posterior part) (inferior rectal nerve). Compared to the ventral part of the anal sphincter, it informs on the distal nervous conduction of the pudendal nerve (falciform process and/or Alcock tunnel and some times sacrospinous ligament)). We subtract the value of the sacral reflexes obtained from the ventral quadrant from that obtained from the caudal one.

- Puborectal muscle (levator ani nerve). Compared to the caudal quadrant, it informs us on the nervous conduction of the pudendal nerve when crossing the sacrospinous ligament. We subtract the value of the sacral reflexes of the caudal quadrant to that of the puborectal fascicle.

Example

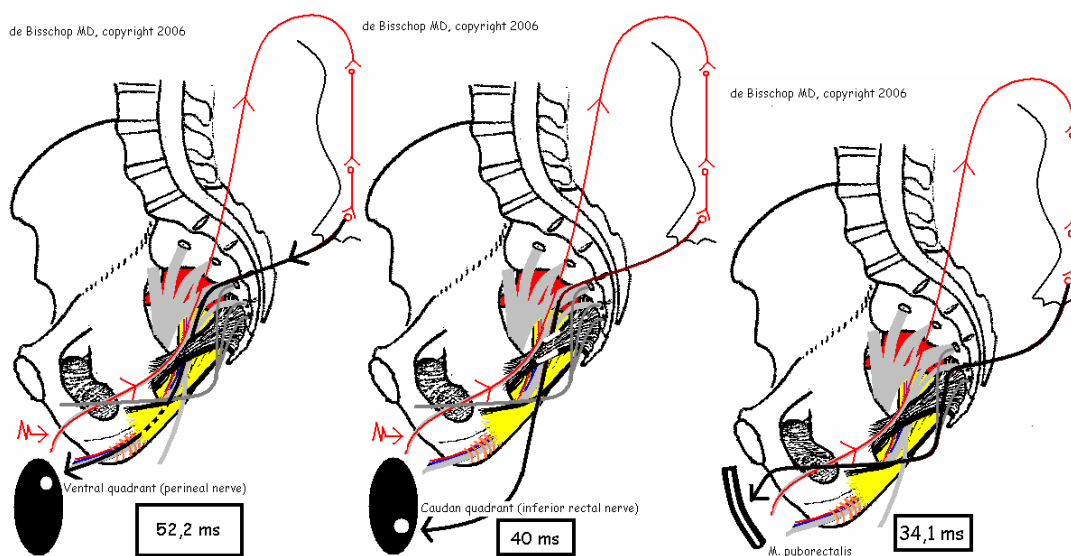


1. Ventral quadrant 52.2 ms

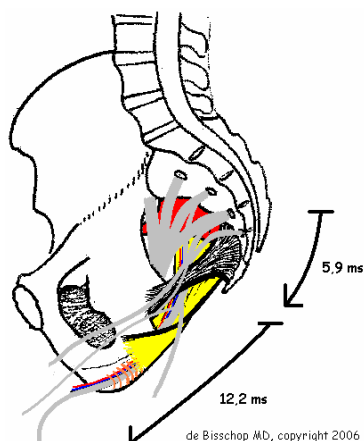
2. Caudal quadrant 40 ms

3. Puborectal muscle 34.1 ms

- Time of nerve conduction distal to the sacrospinous ligament:
 $52,2 - 40 = 12,2 \text{ ms}$ ($N < 3,5 \text{ ms}$) \Rightarrow slowing of the nerve conduction at the level of the falciform process and/or Alcock tunnel
- Time of nerve conduction on the level of the sacrospinous ligament:
 $40 - 34,1 = 5,9 \text{ ms}$ ($N < 2 \text{ ms}$) \Rightarrow slowing of nerve conduction on the level of the sacrospinous ligament



Stimulation at the level of the dorsal nerve of the clitoris/penis



Intraoperative monitoring

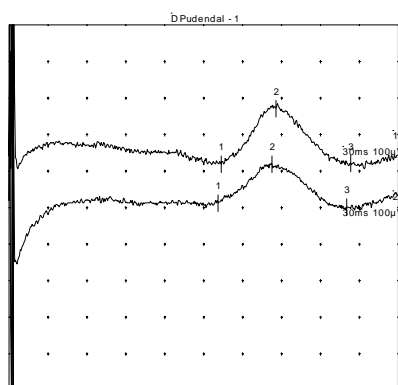
In an Intraoperative methodology by endocavitary stimulation we measure the terminal motor latency of the pudendal nerve. Patient under anaesthesia.

Stimulation is performed close to the ischial spine using a special electrode fixed on a finger stall. Recording is done by a needle electrode inserted in the ventral quadrant of the external anal sphincter.

These intraoperative motor terminal latencies of the pudendal nerve allow the validation of the "staged sacral reflexes". The site of the slowing of nervous conductions of the pudendal nerve, evoked during the study of the sacral reflexes, was confirmed during the procedure by intraoperative motor terminal latencies.

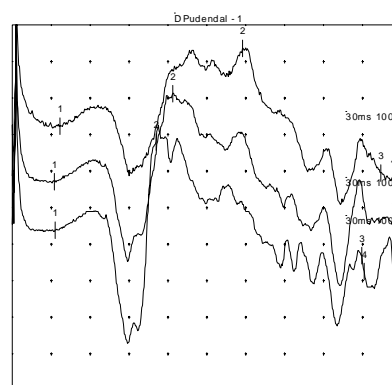
Example:

Before decompression



Terminal motor latency: 15,55 ms
Surface: 0,5 mVms

After decompression

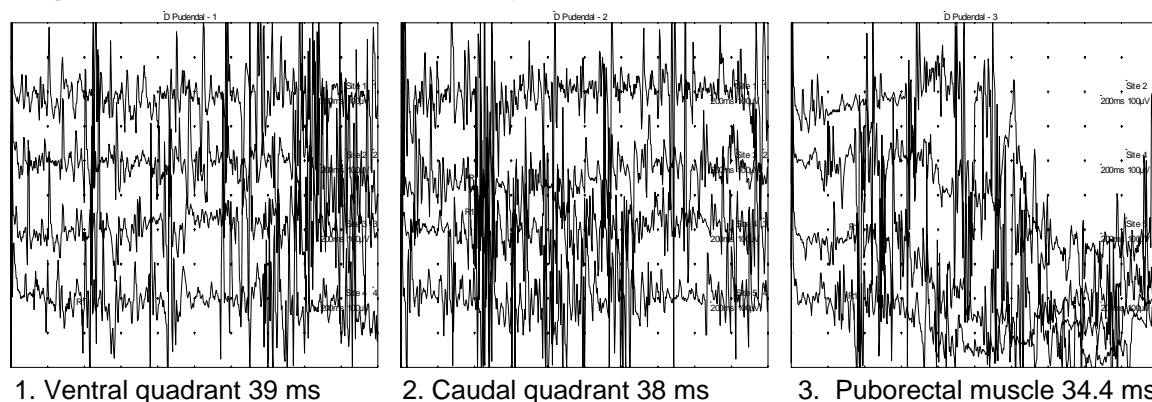


Terminal motor latency: 3,10 ms
Surface: 2,6 mVms

The intraoperative recordings show that terminal latencies gradually pass from 15,55 ms to 3,10 ms and that the surface of the potential passes from 0,5 mVms to 2,6 mVms. One can deduce from it an improvement of the nervous conductions and a significant release of the number of nervous fibers, which could evoke a state of a partial

functional block. In this example, the "staged" sacral reflexes evoked a slowing down of the pudendal nerve conduction at the level of the sacrospinous ligament and the surgery under intraoperative recordings confirmed an entrapment at the same level.

"Staged" sacral reflexes of this example:



- Time of nerve conduction distal to the sacrospinous ligament:
 $39 - 38 = 1 \text{ ms}$ ($N < 3,5 \text{ ms}$) \Rightarrow normal conduction at the level of the falciform process and/or Alcock tunnel
- Time of nerve conduction on the level of the sacrospinous ligament:
 $38 - 34,4 = 3,6 \text{ ms}$ ($N < 2 \text{ ms}$) \Rightarrow slowing of nerve conduction on the level of the sacrospinous ligament

Conduction times are identical in awaked patients and those under anaesthesia. (PROPOFOL, SUFENTANIL, HALOGENE). Experimental controls on the fibular common nerve suggest that motor nerve velocity and distal latency are not modified by this type of general anaesthesia.

Conclusion

This innovative electromyographic investigation makes it possible to locate the site of the pudendal nerve entrapment that the PNTML cannot do.

References

1. Baurtant E, Bisschop (de) E, Viani-Elies V, et al. La prise en charge moderne des névralgies pudendales. *J Gynecol Obstet Biol Reprod* 2003;32:705-712.
2. Beco J, Mouchel J. Intérêt de la décompression du nerf pudendal pour le chirurgien périnéologue. *Gynäikeia* 1997;2:44-7.
3. Bisschop (de) E, Baurtant E. Exploration électrophysiologique périnéale dans le cadre de la névralgie pudendale : nouveaux concepts. Proceedings of the Annual Meeting Le Choix des Armes, Marseille, France, 10-11 march 2006 : 1-8.
4. Bisschop (de) G, Bisschop (de) E, Commandré F. Les syndromes canalaires. Paris : Masson, 1997.
5. Bisschop (de) G, Bisschop (de) E. Le nerf normal et pathologique: répercussions électrophysiologiques. In: Beco J, Mouchel J, Nelissen G. La périnéologie. Comprendre un équilibre et le préserver. Verviers : Odysée 1372, 1998:10:1-19.
6. Bisschop (de) G, Dumoulin J. Electromyographie clinique. Paris : Masson, 1992.
7. De Ribet, RM. Anatomie schématique de l'appareil nerveux. Paris : Doin, 1953.
8. Gagnard C, Godlewski G, Prat D, et al. The nerve branches to the external anal sphincter: the macroscopic supply and microscopic structure. *Surgical-Radiologic Anatomy* 1986;8:115-119.
9. Hovelacque A. Anatomie des nerfs crâniens et rachidiens et du système grand sympathique chez l'homme. Paris : Doin, 1927.
10. Kopell H, Thompson W. Peripheral entrapment neuropathies. Huntington NY, Krieger Pub, 1976.
11. Rouvière H. Anatomie humaine. Paris : Masson, 1959.
12. Shafik A, El Sherif M, Youssef A, Olfat E. Surgical anatomy of the pudendal nerve and its clinical implications. *Clin Anat* 1995;8:110-5.
13. Sobota J. Atlas d'Anatomie Humaine. Tome 4. Paris : Maloine ; 1977.
14. Vodusek D. Evoked potential testing. *Urol Clin North Amer* 1996,23:428-446.